

CLINICAL PRACTICE

Use of arteriovenous fistula in children with bleeding disorders

Victoria West

Haemophilia and associated bleeding disorders are chronic conditions that require easy, accessible, and reliable venous access for treatment. Peripheral venous access is traditionally the first option considered for prophylaxis. The initial introduction of prophylaxis to a child is during the first two years of life, and peripheral access can be problematic. Central venous catheters (CVC), for example port-a-caths, are widely used among this group; however, these devices require surgical insertion and are not without their own complications. Data were collected on venous access methods used at the paediatric centre at the Evelina London Children's Hospital, where 242 children are registered at the comprehensive care centre, 48 of whom have a severe bleeding disorder. Of these 48, 27 have a CVC currently (PICC n=1, Port-a-Cath n=25, Hickman line n=1) and 3 have an arteriovenous fistula (AVF). Patient 1 is a 12 year-old boy with severe haemophilia A and an intracranial haemorrhage at the age of 9 months. He remains on prophylaxis and had an AVF created 5 years ago following repeated port-a-cath infections and poor venous access. Patient 2 is a 7 year-old boy with severe haemophilia B and an inhibitor, who has also had repeated port-a-cath infections. An AVF was constructed 2 years ago. Patient 3 is a 12 year-old girl with type III von Willebrand disease and an inhibitor. Due to need for regular factor treatment in the context of poor venous access, an AVF was formed. We have had a 100% success rate with all three AVFs at a follow-up period of 8-69 months. Our experience suggests AVF is a viable option of venous access in patients with haemophilia and other bleeding disorders, especially so for children with repeated CVC infections or poor peripheral venous access. However, this is not a straightforward option and further evidence on long-term use based on multicentre research will be beneficial in managing AVF in this group of patients.

Keywords: haemophilia, prophylaxis, venous access, arteriovenous fistula

Haemophilia and associated bleeding disorders are chronic conditions that require easy, accessible, and reliable venous access for treatment. Peripheral venous access is

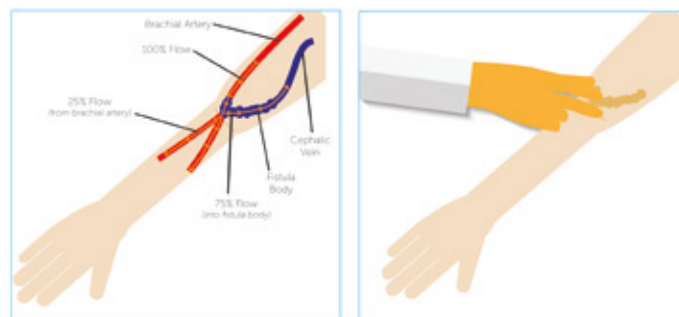


Figure 1: The anatomic location of brachiocephalic AVF

traditionally the first option considered for prophylaxis.

Prophylaxis was introduced in Sweden in 1958 in order to prevent joint bleeding, which in turn progresses to the development of arthropathy. It is initially introduced to children with bleeding disorders during the first two years of life and peripheral venous access at this age can be problematic [1,2] some environment. Central venous catheters (CVC), in particular port-a-caths, are widely used to facilitate home treatment in young children; however, these devices require surgical insertion and are not without their own complications, including repeated infections, thrombosis and body issues in girls facing puberty [3,4,5]. Nevertheless, peripheral access and CVC remains the route of choice in paediatric venous access [3].

An arteriovenous fistula (AVF) is an abnormal connection between an artery and a vein and offers another form of venous access. AVF has been used in a number of haemophilia centres in Europe, and have been found to be an 'attractive solution' [4]. Studies on use of AVF in patients with bleeding disorders have shown them to be less problematic compared with CVCs [4-6]. In this report we describe our experience with the use of AVF for routine venous access in three children with severe inherited bleeding disorders.

Materials and methods

Data were collected on venous access methods used at the paediatric centre at the Evelina London Children's Hospital. 242 children are registered at the comprehensive care centre, 48 of whom have a severe bleeding disorder. Of these, 27 have a CVC currently (PICC n=1, port-a-cath n=25, Hickman line n=1) and 3 have an arteriovenous fistula (AVF). Patients with AVF include two boys and one girl:

Victoria West, Paediatric Haemophilia Clinical Nurse Specialist, Evelina London Children's Hospital, London SE1 7EH. Email: Victoria.West@gstt.nhs.uk

- Patient 1 is a 12 year-old Caucasian boy with severe haemophilia A, who sustained a traumatic intracerebral bleed, subsequently leading to quadriplegic motor disorder from the age of 9 months. He remains on prophylaxis with recombinant factor VIII (rFVIII). As a result of repeated port-a-cath infections and poor venous access, an AVF was fashioned 5 years ago. The procedure was uneventful and covered with rFVIII concentrate.
- Patient 2 is a 7 year-old boy of West African origin with severe haemophilia B and an inhibitor. He requires daily treatment with recombinant factor VIIa (rFVIIa). He has also had repeated port-a-cath infections and developed a phobia of needles. He has poor venous access and an AVF was constructed 2 years ago. The initial fistula formation was associated with stenosis in the left fistula vein above the brachiocephalic anastomosis, hence a fistuloplasty was performed by the interventional radiologist. Post-procedure angiography showed satisfactory appearance of the fistula.
- Patient 3 is a 12 year-old Asian girl with type III von Willebrand disease and an inhibitor. Due to need for regular factor treatment in the context of poor venous access and the onset of puberty, an AVF was formed under von Willebrand factor cover. The procedure was tolerated well and there were no immediate complications.

Patient characteristics are presented in Table 1. In each case, the AVF formation procedure was performed under general anaesthesia by the paediatric renal transplant surgeon. All three patients had upper limb imaging scans prior to the procedure to evaluate both arterial and venous systems. The procedures lasted an average of 1.5 hours, with a minimum time of 40 minutes and a maximum time of 2 hours, and the patients spent a mean of 3.6 days in hospital (minimum admission time was 3 days, maximum 5 days).

Results

To date, the success rate with all three AVFs at our centre

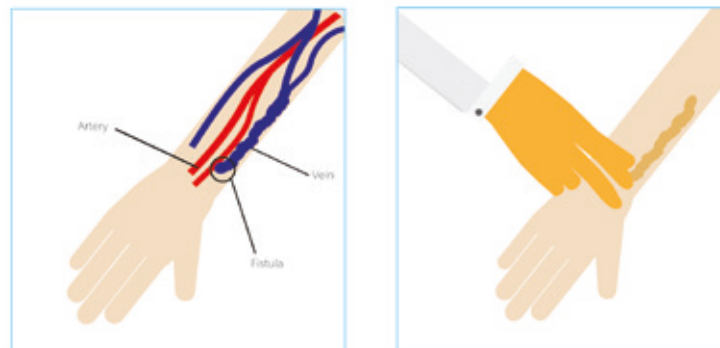


Figure 2: The anatomic location of radialcephalic AVF

has been 100%. Despite the need for even more frequent venous access at times of bleeding episodes, there have been no problems in the patients accessing the AVF over a follow-up period of 8-69 months. Thus, the AVF in all three patients has proven to be a vital and reliable route of venous access to ensure the administration of prophylaxis, with added ease in locating the AVF as noted in other studies [7].

Discussion

AVF is an anastomosis that redirects arterial blood flow into a vein. In time, it becomes dilated due to the new haemodynamic conditions. Over a period of 6-12 weeks the lumen of the vein widens, thus enabling the venous blood flow to increase [10]. The vein then becomes suitable for puncture and the use of prophylaxis or other alternative treatment can begin. In haemophilia the brachial artery (Figure 1) is preferred for use, as research suggests that the radial artery (Figure 2) is related to a higher rate of failure [6]. AVF is the recommended vascular access for haemodialysis patients; however, it is now becoming an increasingly viable alternative form of access, for the use of prophylaxis in haemophilia and other related bleeding disorders [8,9,14].

AVF access

We acknowledge that our report is based on very few patients. However, all three patients have achieved a success rate of 100% at a follow-up period of 8-69 months and no

Table 1: Patient demographics

	Age at formation of AVF	Sex	Ethnic origin	Treatment / disorder	Anatomic location of AVF	Indication	Follow-up period	Complications
Patient 1	7 years 8 months	Male	Caucasian	Alternate day rFVIII / Severe haemophilia A	Brachiocephalic	Repeated port-a-cath infections, poor venous access	69 months	None to date.
Patient 2	6 years 1 month	Male	African	Once-twice daily rFVIIa / Severe haemophilia B with inhibitor	Brachiocephalic	Poor venous access	34 months	None to date
Patient 3	11 years 3 months	Female	Asian	Alternate day vWF concentrate / Type III von Willebrand Disease	Radialcephalic	Poor venous access / female just at the start of puberty	8 months	None to date

further complications have been found. We have found AVF to be a valuable substitute in achieving effortless venous access, in particular for children who have suffered repeated port-a-cath infections and those with poor superficial venous access [1]. Modern prophylaxis management in haemophilia and associated bleeding disorders relies on easy venous access to administer treatment and it is essential to be able to comply with treatment regimens. Traditionally in haemophilia and related bleeding disorders, peripheral access and central venous catheters (CVC), such as port-a-caths, are used in the administration of prophylaxis [11], methods of venous access which have their own complications.

In a three-year study of 27 patients, Santagostino et al. found that AVFs were accepted readily, as treatment became attainable with ease of access [7]. Parents in particular have benefited from this, finding independence in treating their children at home and reducing hospital attendance for venous access [6,14].

Other studies of the use of AVF may also prompt comprehensive care centres to re-evaluate the use of alternate methods as a form of regular access for the treatment of bleeding disorders. Al-Jaishi et al. suggest that AVFs are confirmed to have an exceptional history in long-term patency and durability, with minimal complications [4, 16,15]. Mancuso et al. propose that AVFs are viable and painless alternative, preferred both by patients and health care professionals due to lower rates of infection compared to CVCs [6]. A further advantage cited by the authors is that AVFs are easy to use in the home environment and easily accepted by patients. Increased volume/dose may also be infused through an AVF and is particularly advantageous in ITI patients [5, 8].

Although the AVF is a viable alternative option for intravenous access in haemophilia, it is not without

problems. AVFs have to be constructed under general anaesthesia, exposing the patient to the potential complications associated with anaesthesia. The flow of the AVF must be assessed monthly until maturation, which can take 6 to 12 weeks, impacting school attendance [18]. Complications such as local haematomas at the AVF site, distal steal syndrome, loss of AVF patency, blood overflow, aneurysmal dilatation and inadequate or unsuccessful maturation may occur, which may prevent successful AVF use [5,6,8]. It is also important to note that blood pressures and blood draws should be avoided, on the arm of the AVF and tourniquets may only be applied gently for a brief period to facilitate effortless AVF access [9,17].

While AVF is not the most straightforward option, it could benefit certain patients. Further evidence on the long-term use of AVF in paediatrics will help clinicians, patients and carers in making informed decisions.

Conclusion

Research has shown that AVFs are durable and have the capacity to facilitate repeated venous access with a decreased incidence of infection, compared to that of indwelling central venous access devices [4,18]. Our experience suggests that AVF is a viable option for venous access in patients with haemophilia and other bleeding disorders, and particularly for children with repeated CVC infections or poor peripheral venous access.

Disclosures

The author has advised no interests that might be perceived as posing a conflict or bias.

This is an Open Access article distributed under the terms of the Creative Commons Attribution License (<http://creativecommons.org/licenses/by/2.0>), which permits

Table 2: Comparison of peripheral venous access [12] and Port-a-Cath [13]

	Pros	Cons
Peripheral venous access	Ease of insertion in older children	Difficulty in locating veins in younger children
	Low cost	Potential for local tissue injury
	Minimal complications	Use limited to certain volume/medication
	Low risk of infection	Easily occluded
	Immediate use	Compliance issues in young children
Port-a-Cath	Immediate/easy access for regular treatment	Requires surgical intervention
	Early start of prophylaxis at first bleed	Increased cost
	Low visibility	Increased risk of infections
	Increased volume/dose can be given in ITI	Risk of thrombosis
		Body issues in pre-teen girls
		Risk of bleeding and haematoma
		Risk of general anaesthesia

unrestricted use, distribution, and reproduction in any medium, provided the original work is properly cited.

References

1. Löfqvist T, Nilsson IM, Berntorp E, Pettersson H. Haemophilia prophylaxis in young patients: a long-term follow-up. *J Intern Med* 1997; 24: 395-40.
2. Fischer K, Collins PW, Ozelo MC, Srivastava A, Young G, Blanchette VS. When and how to start prophylaxis in boys with severe hemophilia without inhibitors: communication from the SSC of the ISTH. *J Thromb Haemost* 2016; 14: 1105-9.
3. Komvilaisak P, Connolly B, Naqvi A, Blanchette V. Overview of the use of implantable venous access devices in the management of children with inherited bleeding disorders. *Haemophilia* 2006; 12(6): 87-93.
4. McCarthy MJ, Valentino LA, Bonilla AS, Goncharova I, Taylor A, Pooley TA, Jacobs CE. Arteriovenous fistula for long-term venous access for boys with hemophilia. *J Vasc Surg* 2006; 45(5): 986-90.
5. Santagostino E, Mancuso ME. Venous access in haemophilic children: choice and management. *Haemophilia* 2010; 16(1): 20-24.
6. Mancuso ME, Berardinelli L. Arteriovenous fistula as a stable venous access in children with severe haemophilia. *Haemophilia* 2010; 16(1): 25-28.
7. Santagostino E, Gringeri A, Berardinelli L, Beretta C, Muca-Perja M, Mannucci PM. Long-term safety and feasibility of arteriovenous fistulas as vascular accesses in children with haemophilia: a prospective study. *Br J Haematol* 2003; 123(3): 502-6.
8. Mancuso ME, Berardinelli L, Beretta C, Raiteri M, Pozzoli E, Santagostino E. Improved treatment feasibility in children with hemophilia using arteriovenous fistulae: the follow-up. *Haematologica* 2009; 94(5): 687-92.
9. Chand DH, Valentini RP, Kamil ES. Hemodialysis vascular access options in pediatric: considerations for patients and practitioners. *Int J Pediatr* 2009; 24(6): 1121-8.
10. Wartman S, Rose D, Woo K, Gradman W, Weaver FA, Rowe V. Outcomes with arteriovenous fistulas in the pediatric population. *J Vasc Surg* 2014; 60(1): 170-5.
11. Carslen CG, Taylor SM, Cull D, Langan EM, Snyder BA, Yonky JR, Caldwell RA. AV fistula: a forgotten alternative to venous access. *Ann Vas Surg* 2004; 18(6): 635-9.
12. Stovroff M, Teague WG. Intravenous access in infants and children. *Pediatr Clin North Am* 1998; 45(6): 1373-93.
13. Heibl C, Trommet V, Burgstaller S, Mayrbaeurl B, Baldinger C, Koplmüller R, Kuhr T, Wimmer L, Thaler J. Complications associated with the use of Port-a Caths in patients with malignant or haematological disease: a single centre prospective analysis. *Eur J Cancer Care* 2009; 19(5): 676-81.
14. Santagostino E, Mancuso ME. Barriers to primary prophylaxis in haemophilic children: the issue of the venous access. *Blood Transfus* 2008; 6(2): 12-16.
15. Lok CE. Fistula first initiative: advantages and pitfalls. *Clin J Am Soc Nephrol* 2007; 2(5): 1043-53.
16. Al-Jaishi AA, Oliver OJ, Thomas SM, Lok CE, Zhang JC, Garg AX, Kosa S, Quinn RR, Moist LM. Patency rates of the arteriovenous fistula for hemodialysis: a systematic review and meta-analysis. *Am J Kidney Dis* 2014; 63(3): 464-78.
17. Khair K, Baker K. Therapeutic use of arteriovenous fistula in children with haemophilia <http://www.ncbi.nlm.nih.gov/pubmed/19057498> *Br J Nur* 2008; 17(22): 1396-400.
18. Almási-Sperling V, Galiano M, Lang W, Rother U, Rascher W, Regus S. Timing of first arteriovenous fistula cannulation in children on hemodialysis. *Pediatr Nephrol*. 2016 Apr 25 [Epub ahead of print].

The Journal of Haemophilia Practice

An open-access journal for sharing experience in the care of people with bleeding disorders

www.haemjournal.com

